

***Element 67.00***

**Agati**

# **Contrast Perfusion**

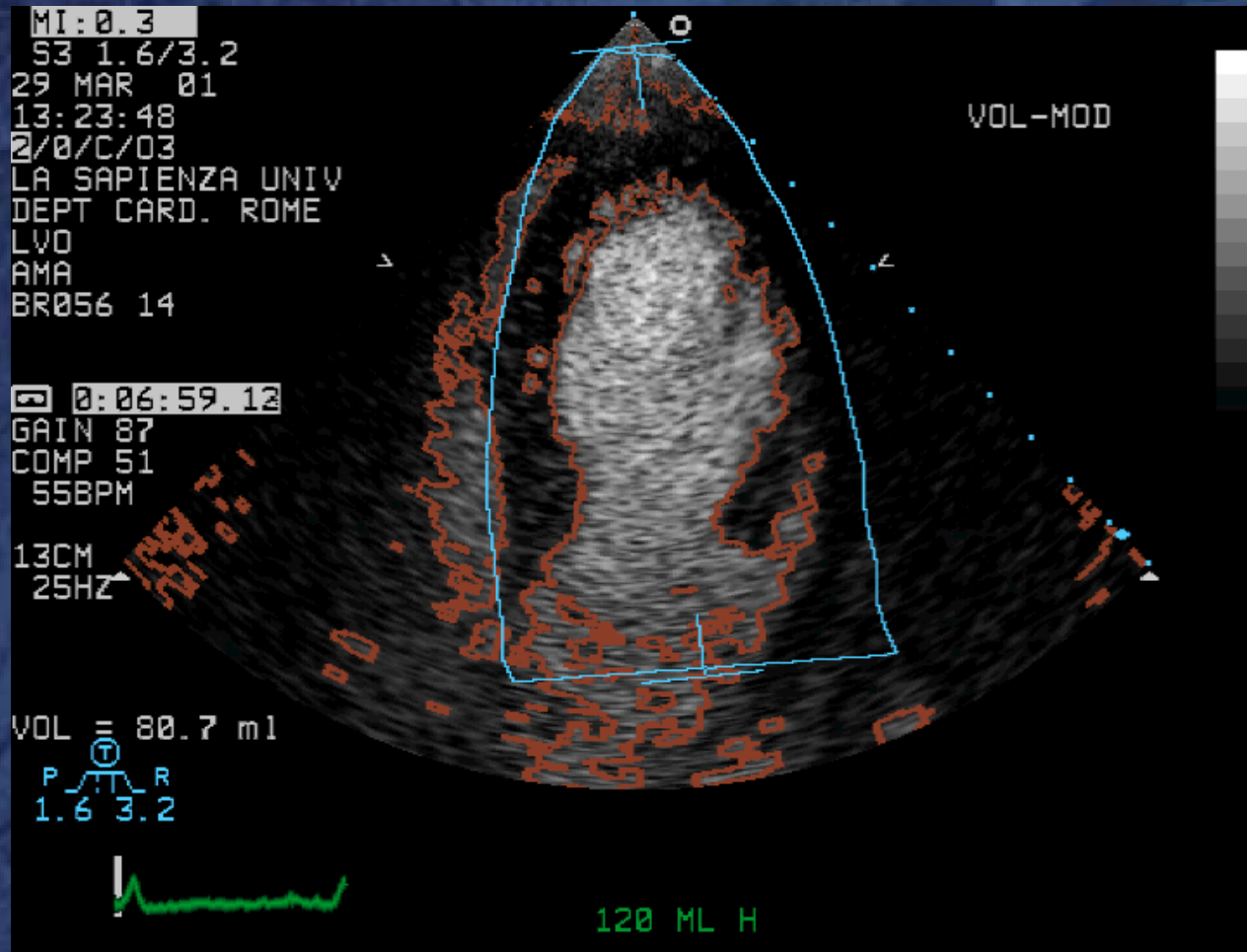
## ***Applications***

- **Endocardial borders**
- **Myocardial flow reserve**
- **Acute coronary syndromes**
- **Reversible perfusion defects**  
*(on-going image processing development)*

**MOVIE**

# Automatic Border Detection

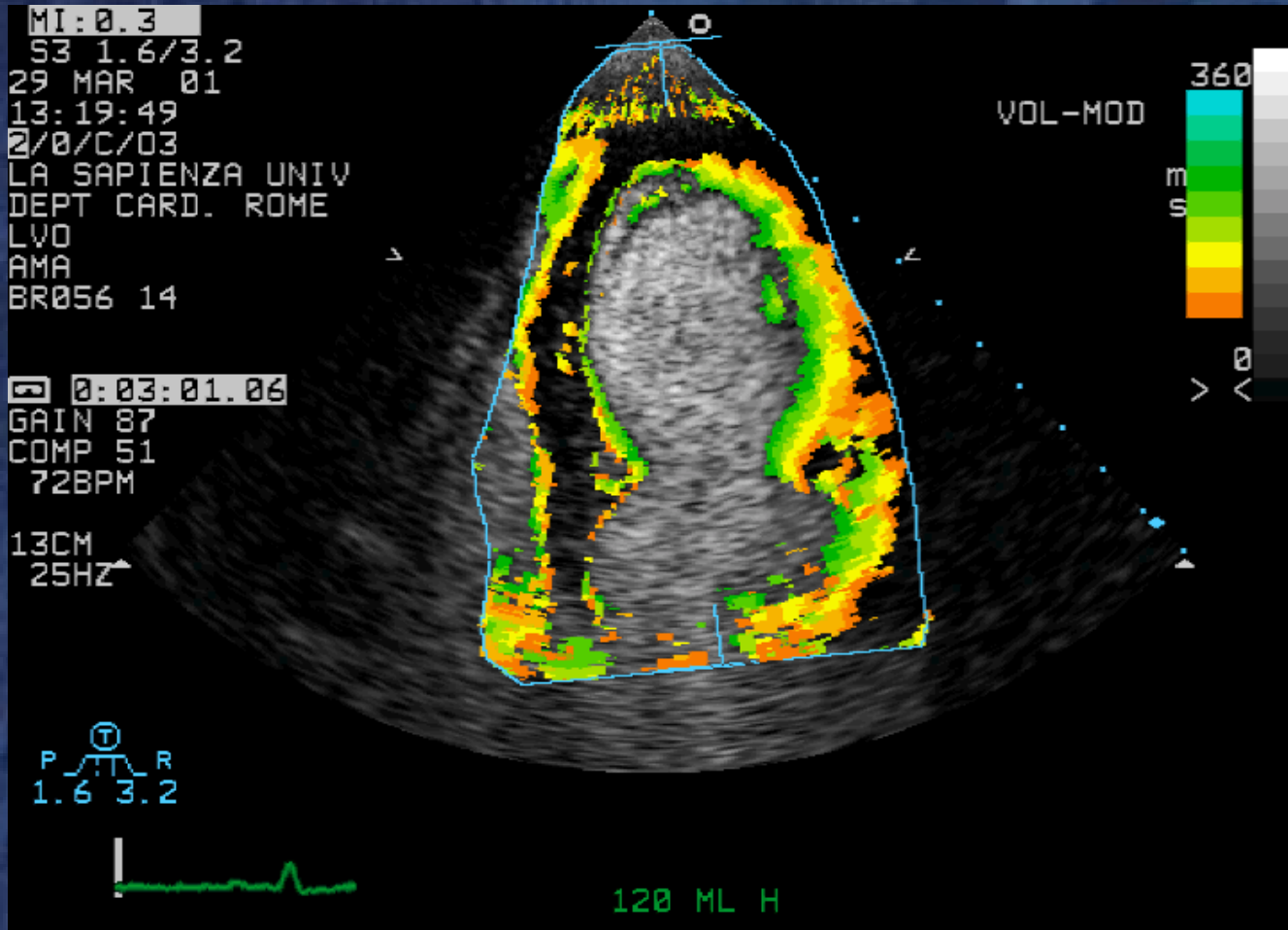
## Apical 4-chamber



**MOVIE**

# Color Kinesis: Systole

## Apical 4-chamber

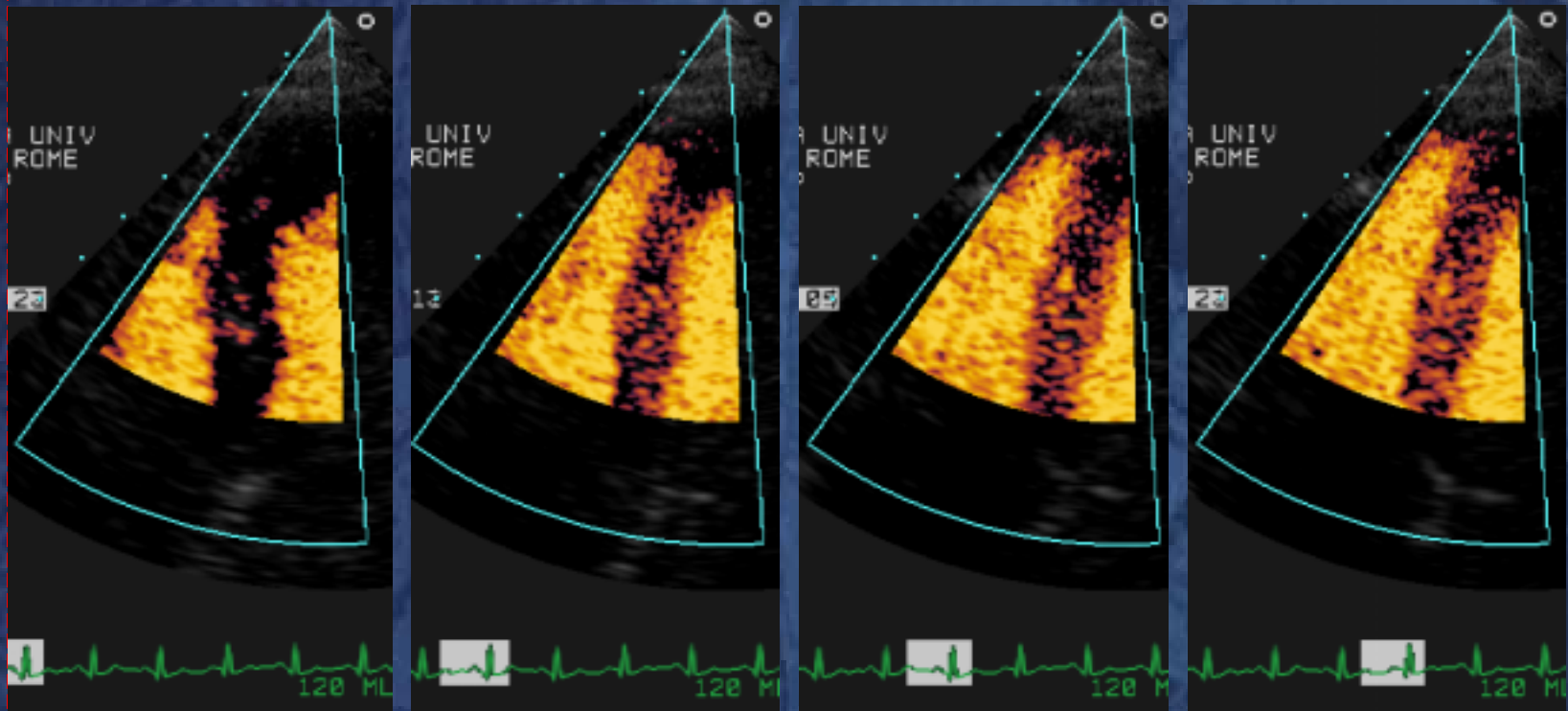


# **Contrast Perfusion**

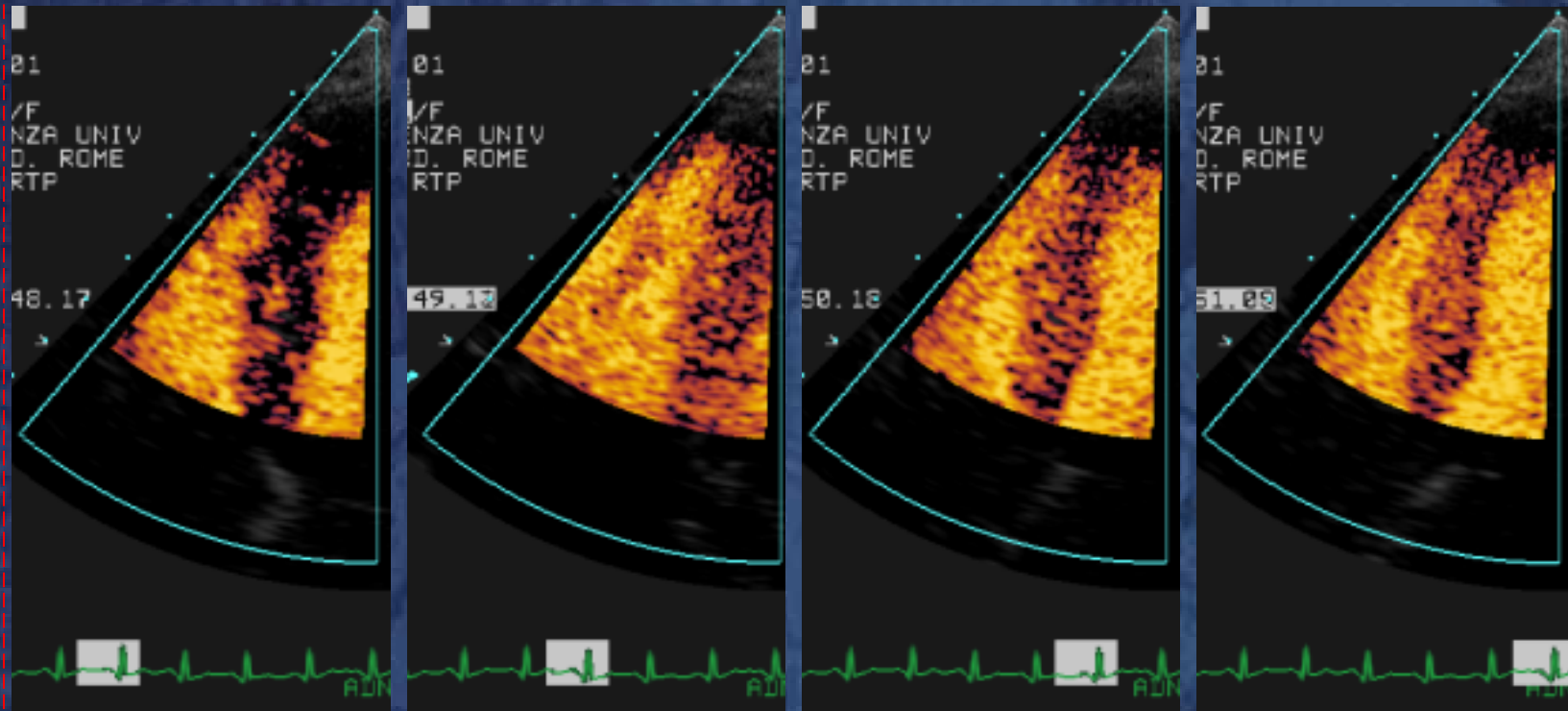
## ***Applications***

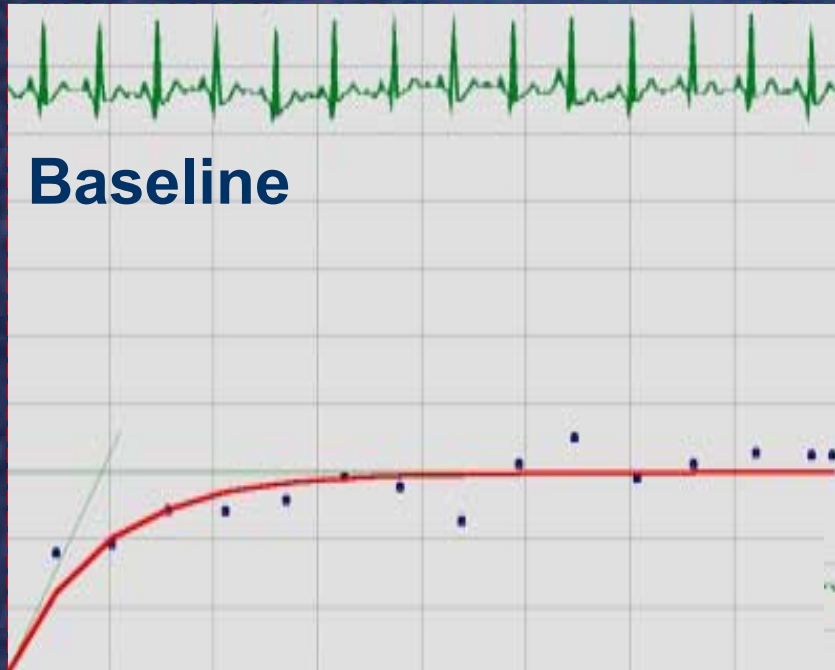
- **Endocardial borders**
- **Myocardial flow reserve**
- **Acute coronary syndromes**
- **Reversible perfusion defects**  
*on-going image processing  
development*

# Baseline

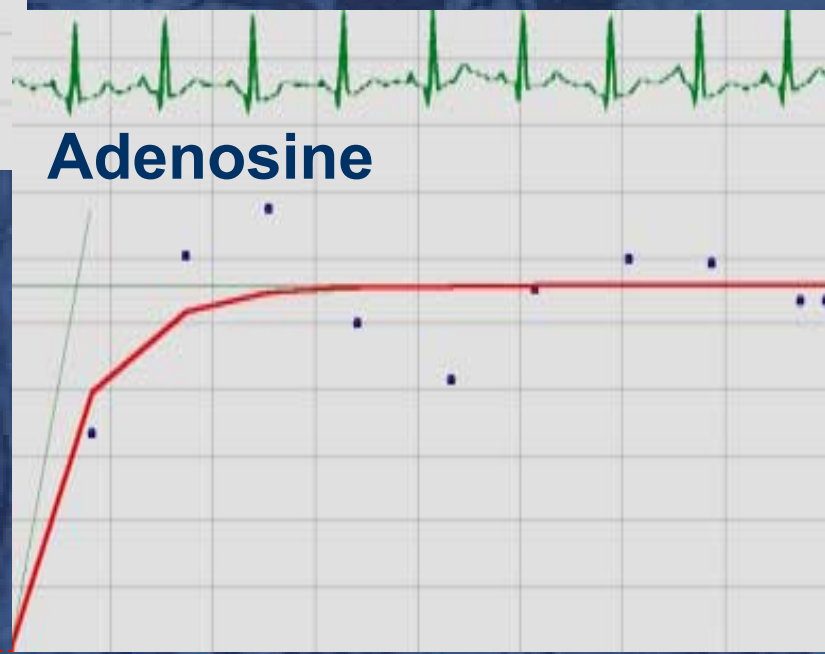


# Adenosine





**Mid LAD territory**



**CFR = 2.5**

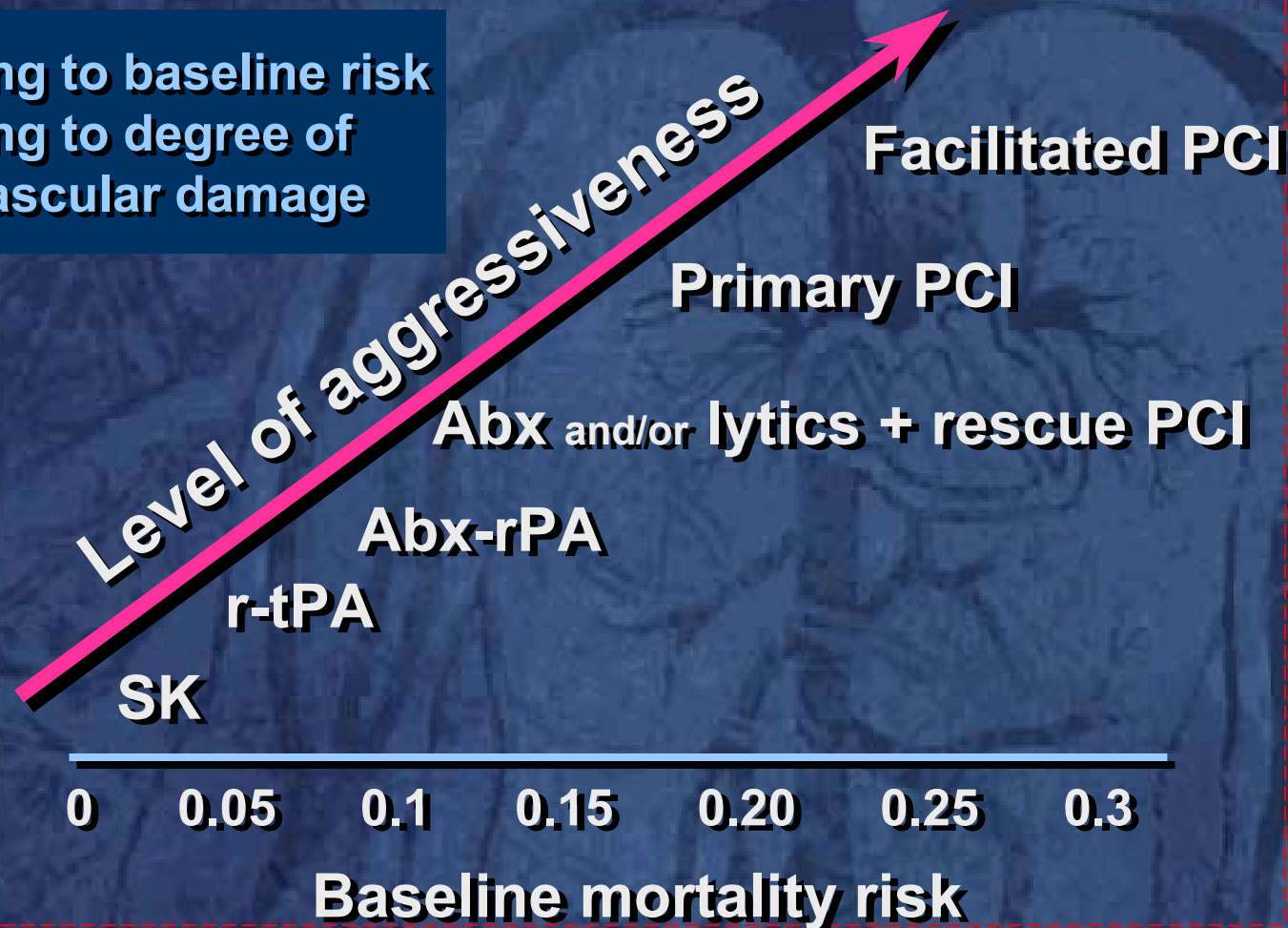
# **Contrast Perfusion**

## ***Applications***

- **Endocardial borders**
- **Myocardial flow reserve**
- **Acute coronary syndromes**
- **Reversible perfusion defects**  
*on-going image processing  
development*

# Tailored Reperfusion Strategy: Acute MI

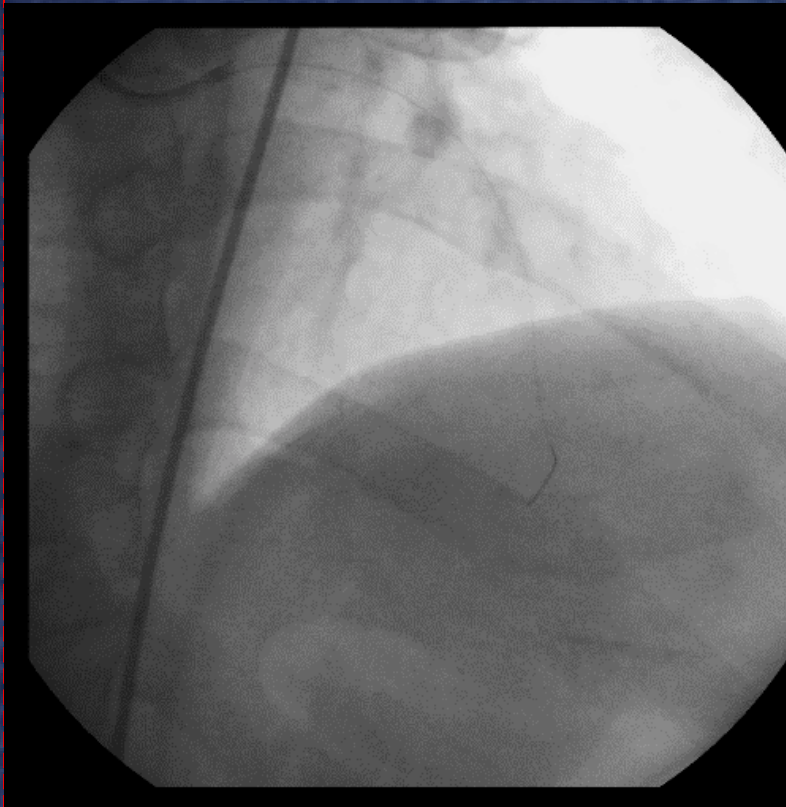
1. according to baseline risk
2. according to degree of microvascular damage



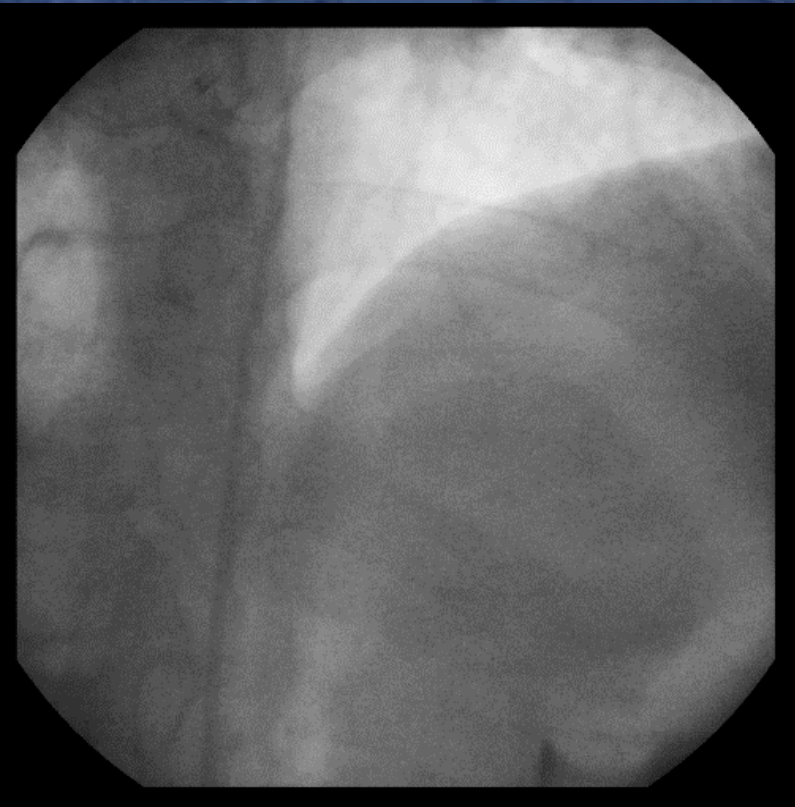
# Case

- 50 y.o. male
- Acute apical infarction
- Failed thrombolysis *iv t-PA*
- LAD stenting + abciximab  
*within 12 hrs*

# MOVIES

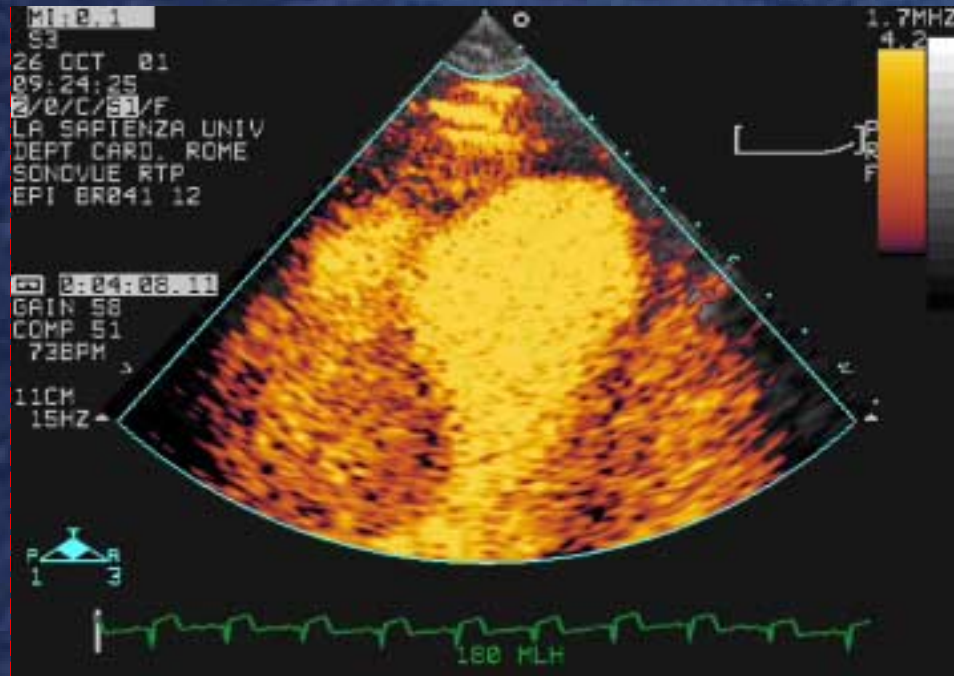


**LAD after iv t-PA**

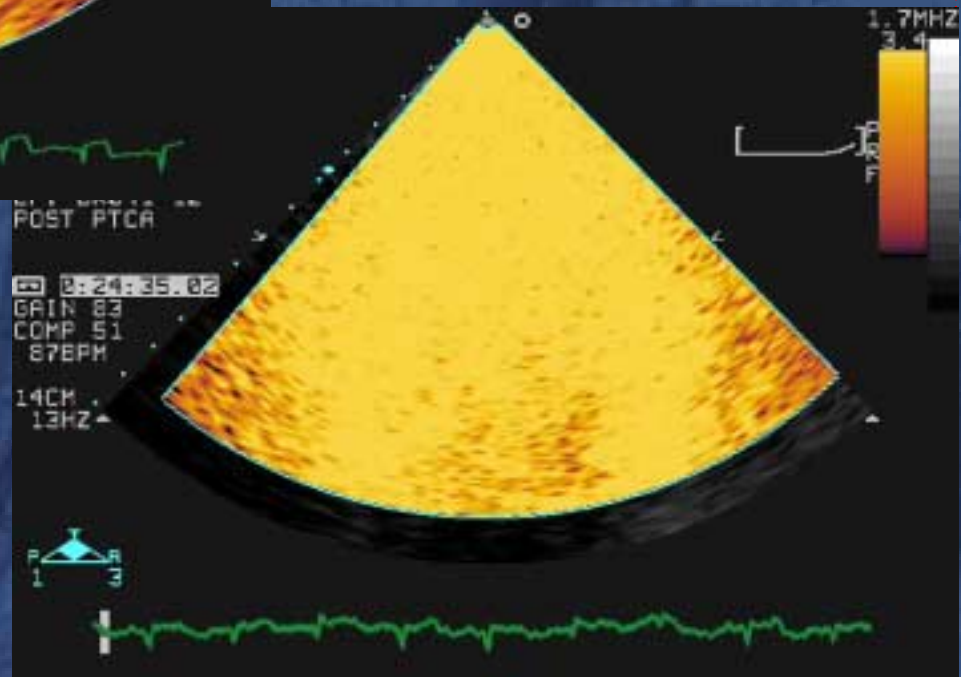


**LAD after PTCA**

# MOVIES



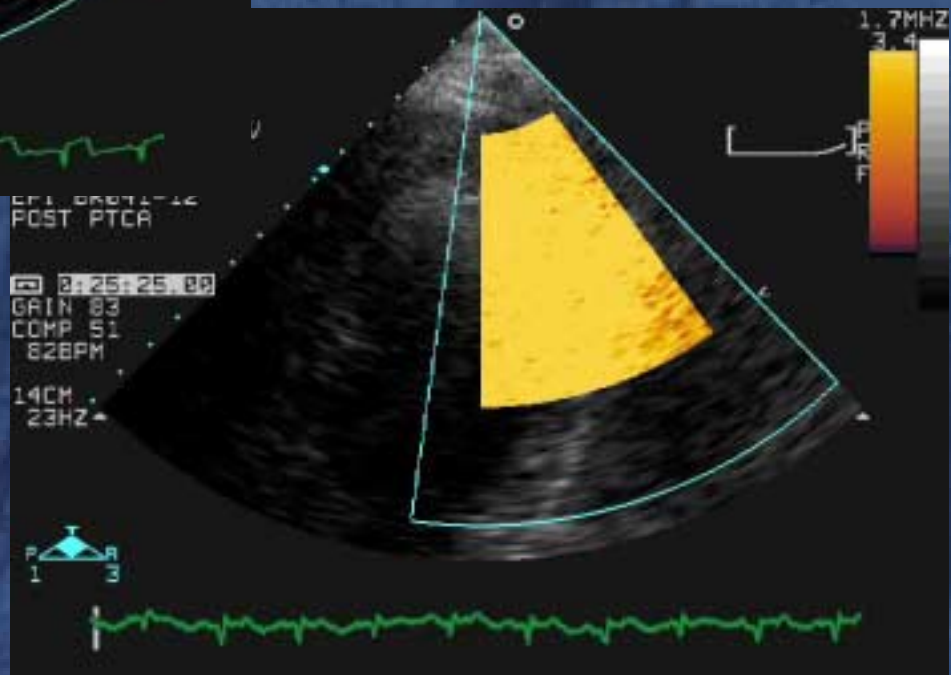
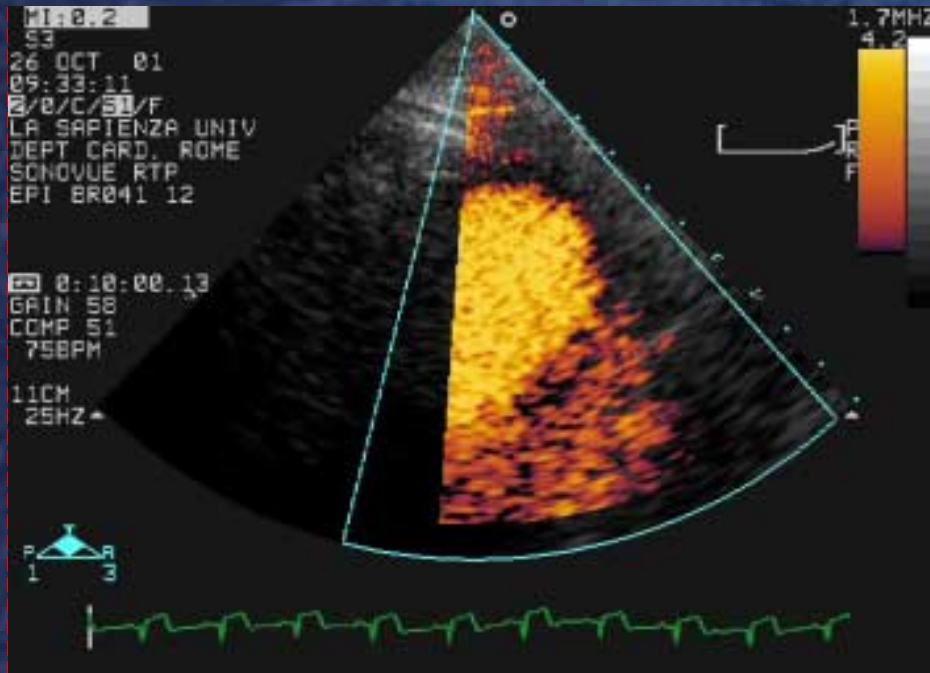
After iv t-PA



After LAD stenting

# MOVIES

After iv t-PA



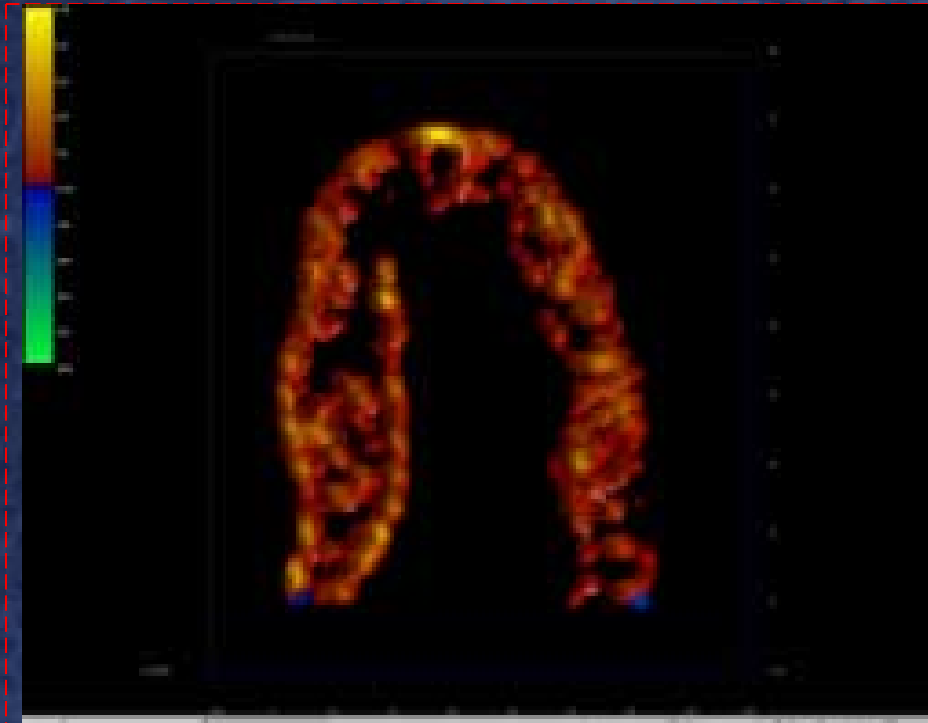
After LAD  
stenting

# **Contrast Perfusion**

## ***Applications***

- **Endocardial borders**
- **Myocardial flow reserve**
- **Acute coronary syndromes**
- **Reversible perfusion defects**  
*on-going image processing  
development*

# MOVIES



**Rest**

**Peak  
Dipyridamole**

