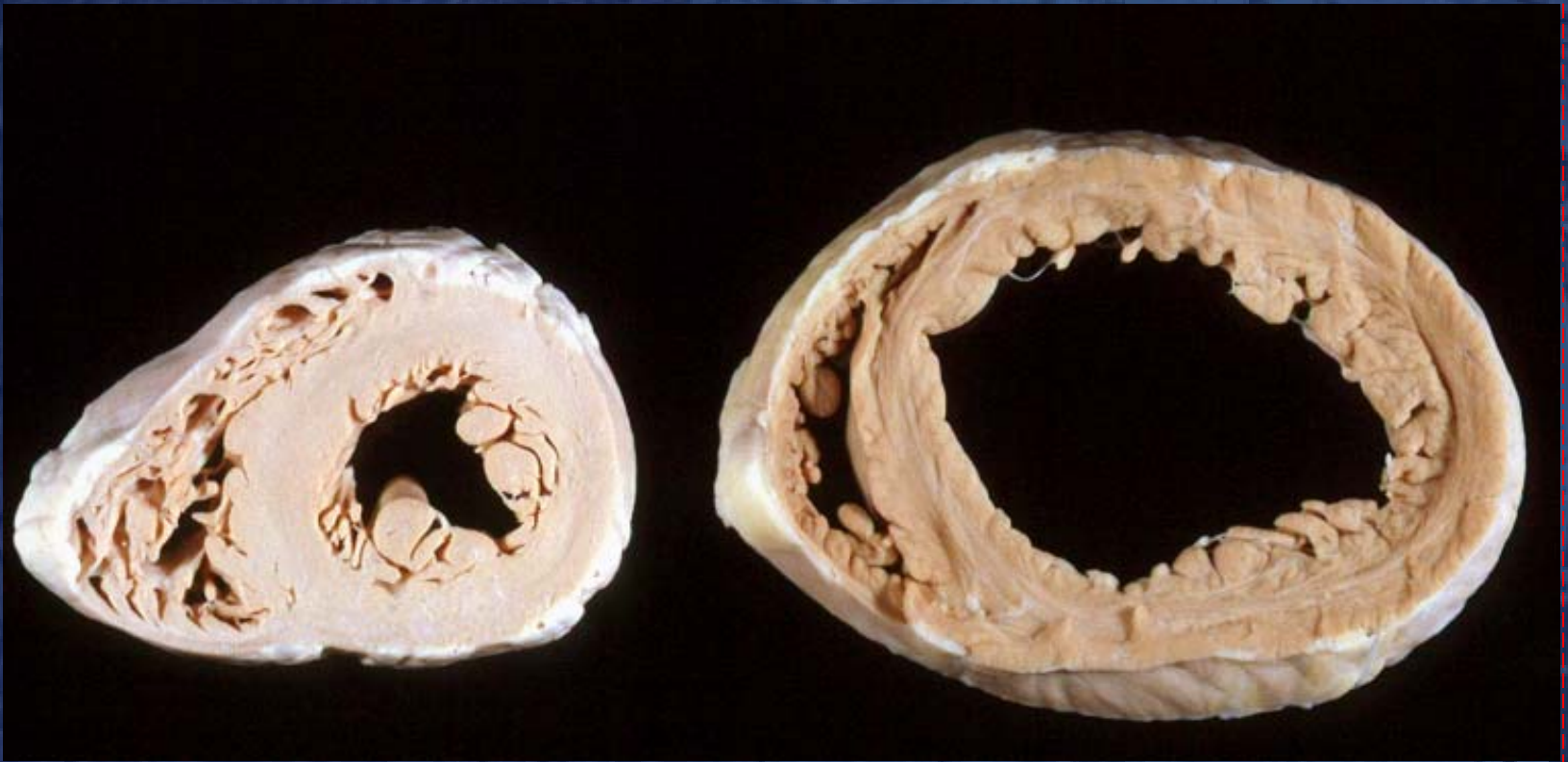


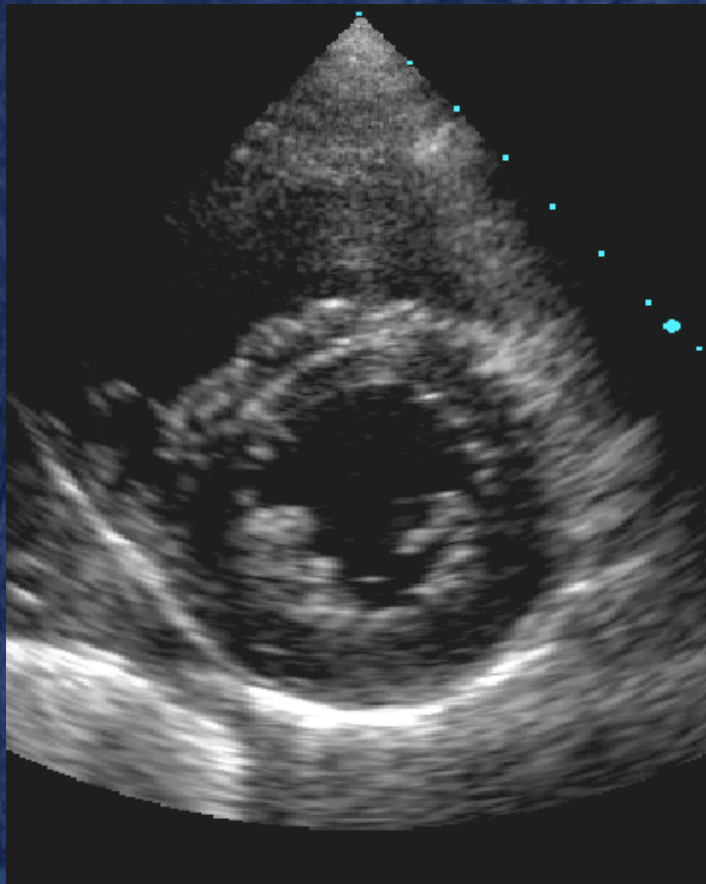
Element 11.00

Adams/K. Kisslo

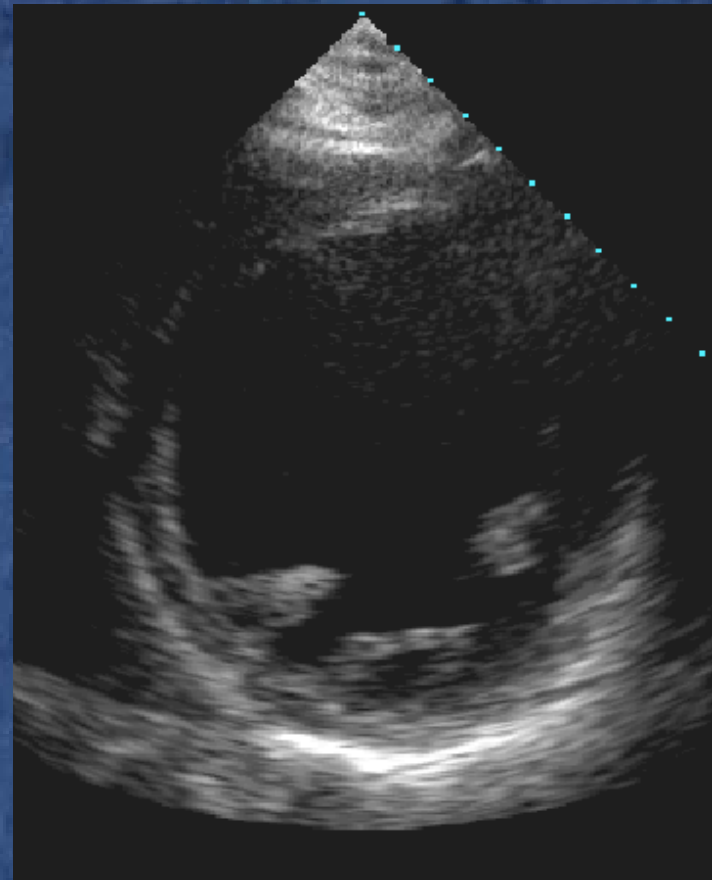


Normal

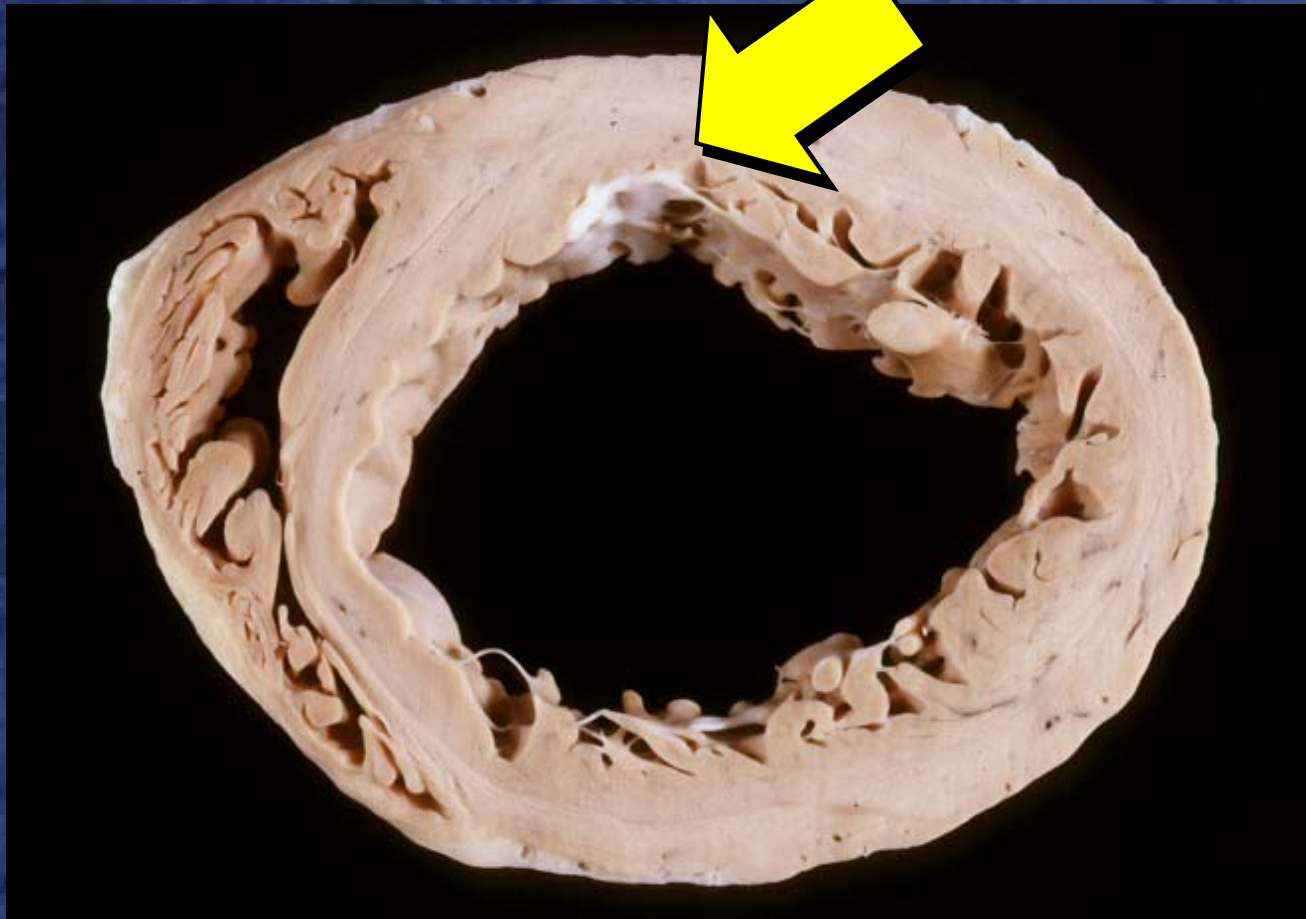
Dilated CM



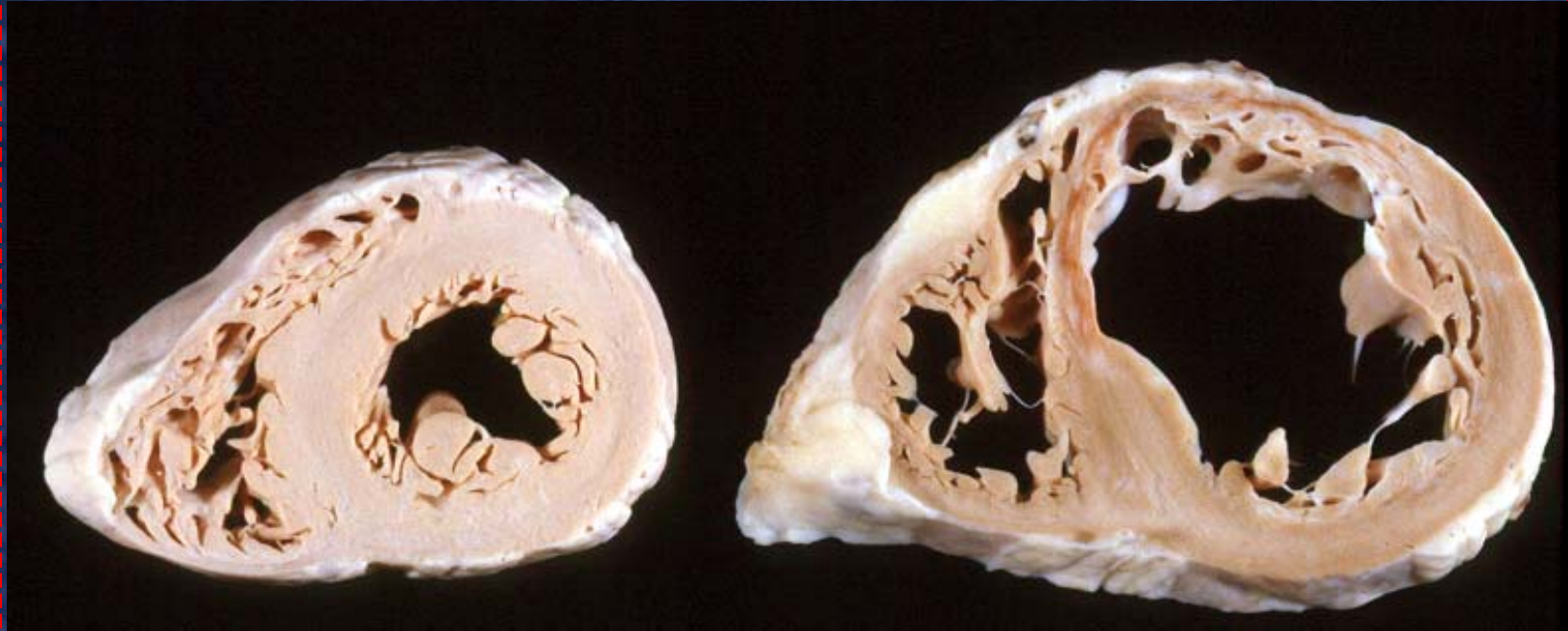Normal



Dilated CM

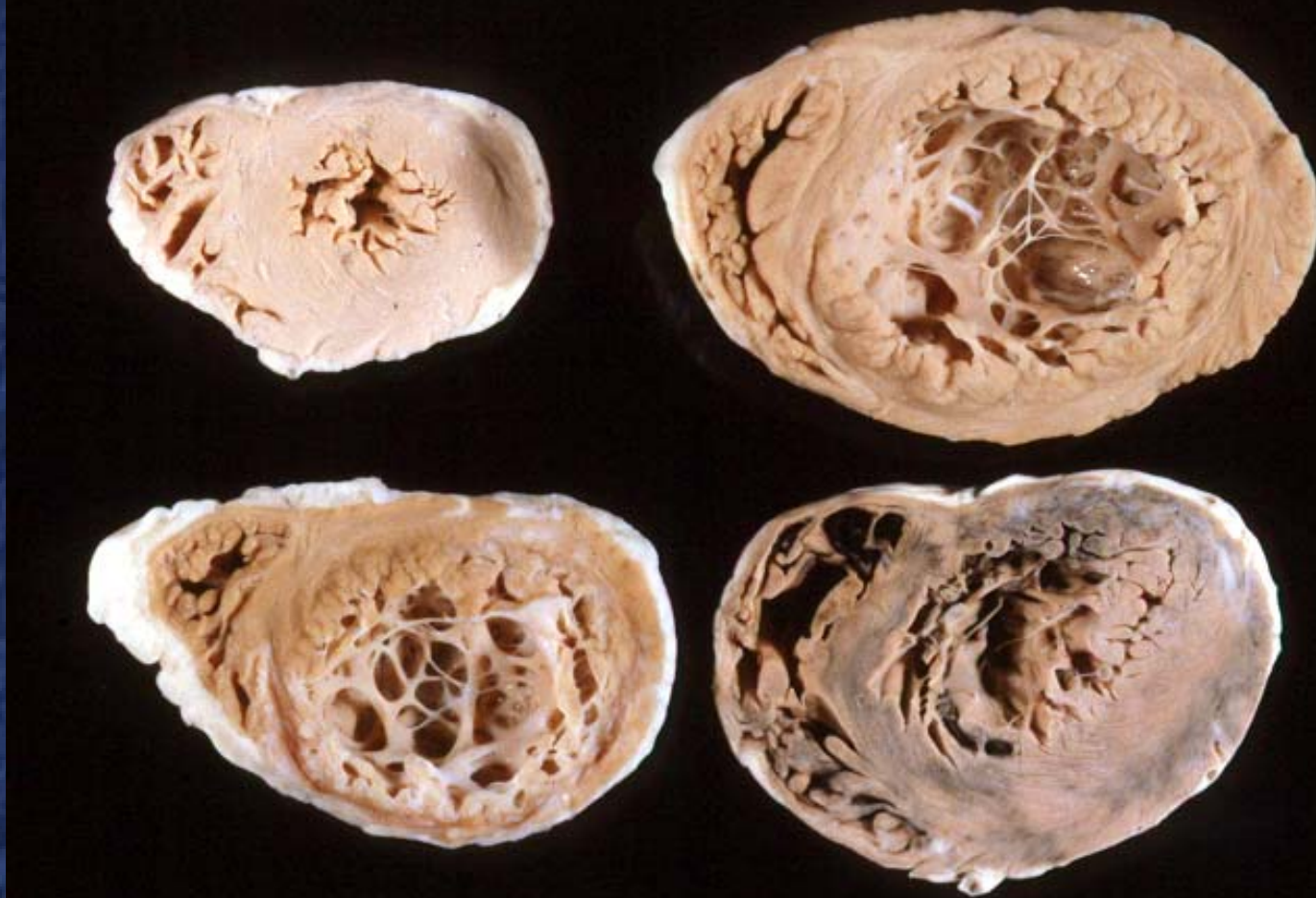

Silent infarctions



Normal

Ischemic CM



Apical trabeculations and thrombi