

1

Systolic Dysfunction in Heart Failure

Michael Feneley, MD
St. Vincent's Hospital
University of New South Wales

ECHOinContext

<http://www.echoincontext.org>

2

Echo Localization Cause of heart failure

- Myocardial - *systolic*
- *diastolic*
- Valvular
- Pericardial

ECHOinContext

There are many causes of heart failure.

<http://www.echoincontext.org>

3

Echo and Systolic Function

- Global function
- Regional function
- Ventricular remodeling
- Contractile reserve / ischemia / viability
- Valve function (MR important)

ECHOinContext

And, there are many ways to look at heart failure.

<http://www.echoincontext.org>

4

Causes of Systolic Myocardial Dysfunction

- Coronary artery disease
- Valvular heart disease
- Hypertension and aging
- Diabetes
- Dilated cardiomyopathy

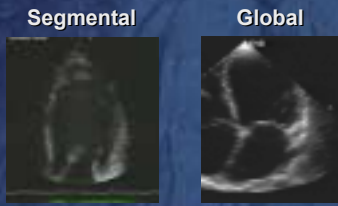
ECHOinContext

Systolic failure and it's causes.

<http://www.echoincontext.org>

5

Echo Morphological Classification of Resting Systolic Dysfunction



ECHOinContext

Systolic failure can be segmental (left with thrombus) or global (right).

<http://www.echoincontext.org>

6

Echo Morphological Classification of Resting systolic dysfunction

- Segmental dysfunction
Focal scarring/dyskinesis most likely ischemic origin but significant regional asymmetry (even without LBBB) often seen in DCM
- Global dysfunction
May be due to ANY of the causes of systolic dysfunction, including CAD
Always exclude CAD!

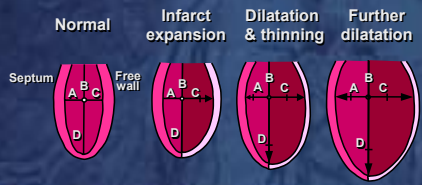
ECHOinContext

Coronary artery disease must be excluded every time there is systolic failure.

<http://www.echoincontext.org>

7

LV Remodeling Post-infarction



ECHOinContext

As we saw in the pathologic segment, infarction can remodel the left ventricle.

<http://www.echoincontext.org>

8

What Can be Measured by Echo?

- LVIDd, LVIDs & fractioned shortening
- LVEDV, LVESV & EF (*which method?*)
- Vcf
- LV mass (*which method?*)
- Cardiac output by LVOT Doppler
- LV dP/dt derived from MR jet

ECHOinContext

Echo can measure many things. All may be useful, but it is impossible to do all.

<http://www.echoincontext.org>

9

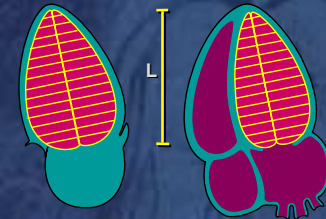
What Can be Measured by Echo?

- Load-independent indices based on PV loops
ESPVR, PRSW (single-beat approaches)
- Regional dysfunction (eg WMS)
qualitative vs quantitative approaches
- Newer methods Tissue Doppler & strain rate, 3D

Even more can be measured to assess systolic failure.

10

Biplane Simpson's Rule

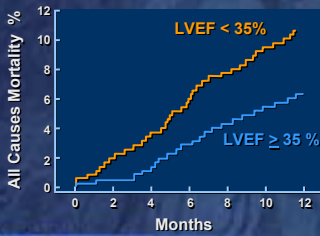


Grayburn, P. Echo in Context

Overall ejection fraction is most common.

11

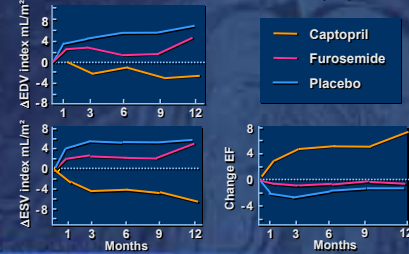
SOLVD Registry Data Prognostic value of LVEF < 35%



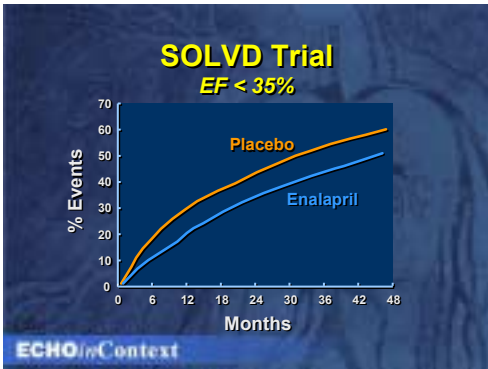
EF indicates prognostic information.

12

Echo EF and LV Failure Treatment Echo volume with Furosemide or Captopril



13



Most big trials indicate that treatment with ACE Inhibition help outcome.

14

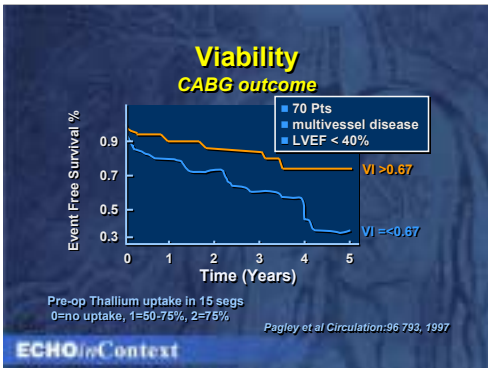
Role of Stress Echo

- Assessing ischemia/viability (DSE) if CAD established by angio
- Symptoms of failure with normal resting EF
- Contractile reserve in valve disease
timing surgical intervention
- DD mild DCM vs "Athlete's Heart"

ECHOinContext

Stress echo has a role in detecting ischemia as the cause, particularly silent ischemia.

15



Viability by stress methods help determine prognosis.

16

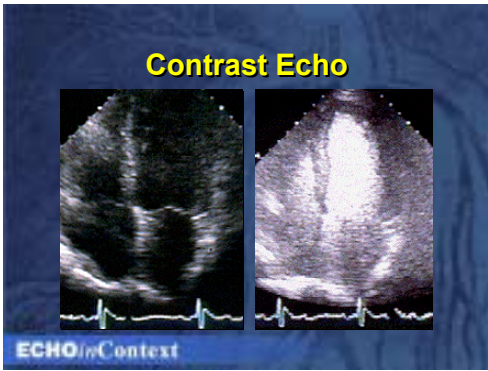
Limitations of Quantitation

- Poor endocardial borders
- Geometric assumptions
- Reproducibility
- Complicated & time-consuming
- Limited evidence of incremental benefit
- Harmonics, contrast, automated border detection and TDI / strain rate may help

ECHOinContext

Like everything, there are limitations to measurement.

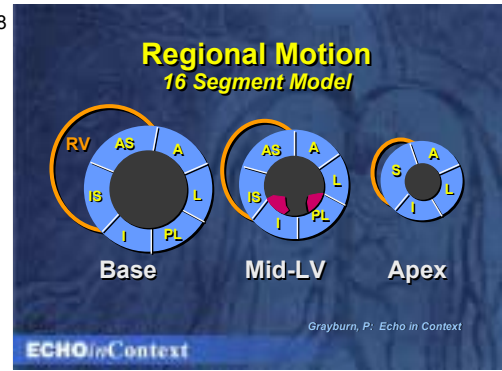
17



Contrast may help to overcome poor visualization of borders.

<http://www.echoincontext.org>

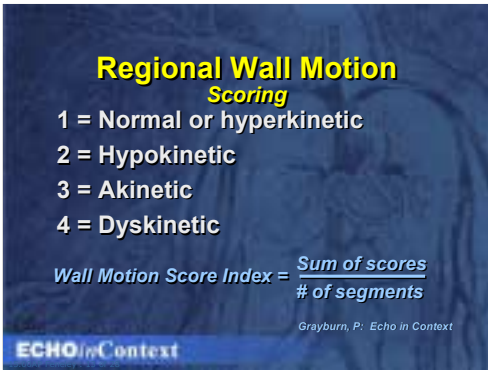
18



Regional, or segmental changes can also be assessed.

<http://www.echoincontext.org>

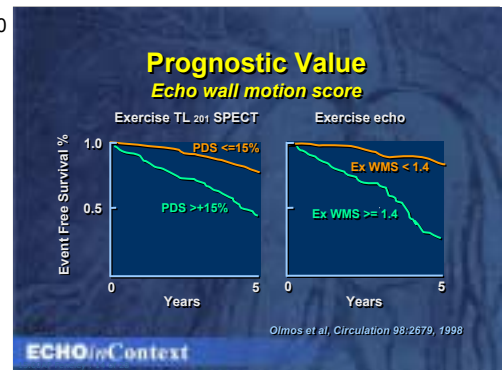
19



And, of course, we can score the walls movement.

<http://www.echoincontext.org>

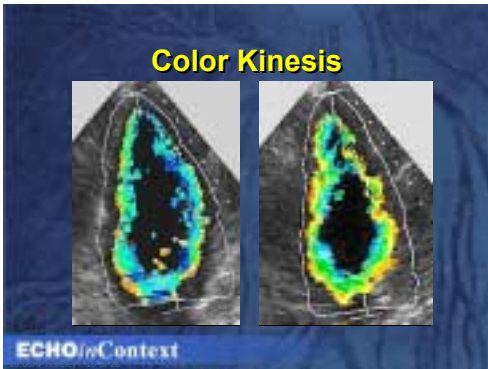
20



Wall scores are useful for prognostic information.

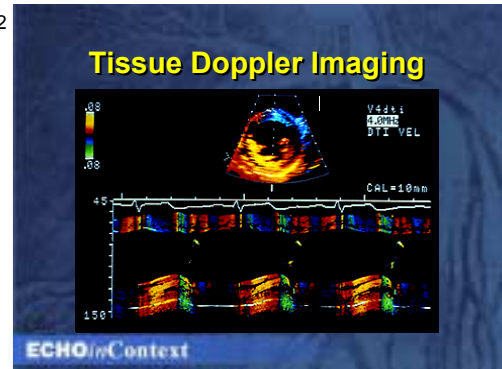
<http://www.echoincontext.org>

21



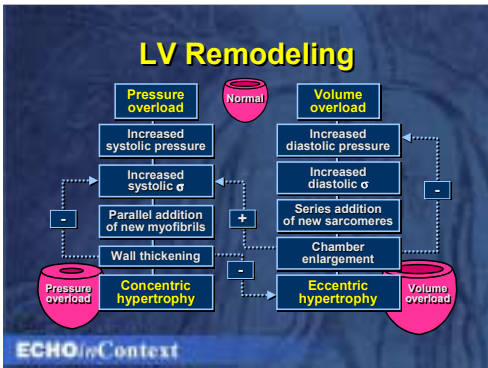
Color wall tracking can help with segmental wall abnormalities.

22



Doppler tissue imaging can help also by showing velocity of walls, not just direction of motion.

23



This is the concept of remodeling.

24

AHA/ACC Guidelines
Echo evaluation of pts with HF

- Symptomatic *initial assessment of LV systolic function (EF)*
- Repeat EF if clinical status changed or significant intervention
- Stress echo after angio to detect ischemia/viability if known CAD & no angina in consideration of revascularization
- Asymptomatic Strong FH / hx cardiotoxic

The recent Guidelines stress the use of echocardiography.

Routine Echo Measures?

- If reasonable LV symmetry
2D-guided M-mode LV dimensions and wall thickness and derived FS%, volumes, EF and mass
- If not
experienced qualitative assessment compares favorably with quantitative volumetric methods

ECHOinContext

<http://www.echoincontext.org>

Routine Echo Measures?

- Single-beat load-insensitive indices
that include non-invasive LV pressure and volume (eg PRSW) may become routine for global contractility assessment soon
- TDI / strain rate may add useful information to regional contractility assessment in some cases

ECHOinContext

<http://www.echoincontext.org>

Echo Tips

Systolic dysfunction

- Normal RV size/contraction
implies better prognosis in DCM
- Preserved LV mass/thickness
implies better prognosis in DCM (eg mass/volume > 0.9)
- Beware of "functional" MR
*may be primary
contributes to LV deterioration even when secondary
may be repairable,
masks severity of LV dysfunction*

ECHOinContext

Here are some "tips".

<http://www.echoincontext.org>